

Topography and Cytoarchitecture of the Motor Nuclei in the Brainstem of Salamanders

GERHARD ROTH, KIISA NISHIKAWA, URSULA DICKE, AND DAVID B. WAKE
Department of Biology, University of Bremen, 2800 Bremen 33, Federal Republic of Germany (G.R., U.D.); Museum of Vertebrate Zoology and Department of Zoology, University of California, Berkeley, California 94720 (K.N., D.B.W.)

ABSTRACT

The organization of the motor nuclei of cranial nerves V (including mesencephalic nucleus), VI, VII, IX, and X is described from HRP-stained material (whole mounts and sections) for 25 species representing five families of salamanders, and the general topology of the brainstem is considered. Location and organization of the motor nuclei, cytoarchitecture of each nucleus, and target organs for nuclei and subnuclei are described. The trigeminal nucleus is separated distinctly from the facial and abducens nuclei and consists of two subnuclei. The abducens nucleus consists of two distinct subnuclei, one medial in location, the abducens proper, and the other lateral, the abducens accessorius. The facial nucleus has two subnuclei, and in all but one species it is posterior to the genu facialis. The facial nucleus completely overlaps the glossopharyngeal nucleus and partially overlaps that of the vagus. In bolitoglossine plethodontid salamanders, all of which have highly specialized projectile tongues, the glossopharyngeal and vagus nuclei have moved rostrally to overlap extensively and intermingle with the anterior and posterior subnuclei of the facial nerve. In the bolitoglossines there is less organization of the cells of the brainstem nuclei: dendritic trunks are less parallel and projection fields are wider than in other salamanders. Some aspects of function and development are discussed; comparisons are made to conditions in anurans; and phylogenetic implications are considered.

Key words: motor neurons, feeding behavior, cranial nerves, horseradish peroxidase

The motor nuclei in the brainstem of salamanders (Amphibia: Caudata) have received little attention. In a previous study (Roth and Wake, '85a) we presented preliminary observations on several of these nuclei in one family of salamanders, the Plethodontidae. We here extend our study to all brainstem motor nuclei in this and four additional families and compare our results with those obtained from recent studies of anurans. The major advances of the present study are new information on the trigeminal, abducens, and facial nerves and a more detailed analysis of the topology and cytoarchitecture of the brainstem. Motor nuclei of the cervical spinal cord are considered in a separate publication (Wake et al., '88).

In salamanders the main function of the motor nuclei of the brainstem and the cervical spinal cord is control of feeding. Larval and aquatic adult salamanders use suction

feeding, but terrestrial salamanders all use their tongue to apprehend prey. Feeding on land involves a stereotyped sequence of events: opening the mouth, raising the floor of the mouth and advancing the tongue, propelling the hyobranchial apparatus and attached tongue tip forward out of the mouth, retracting the apparatus with the tongue tip and prey, closing the mouth, and swallowing. The action can be very rapid and the many muscles involved are active at the same time (Thexton et al., '77). The major muscles involved in feeding and their associated brainstem motor nuclei are m. intermandibularis and m. adductor mandi-

Accepted May 23, 1988.

Kiisa Nishikawa's present address is School of Biological Sciences, University of Kentucky, Lexington, KY 40506.

bulae—trigeminus (V); m. depressor mandibulae and m. interhyoideus complex—facialis (VII); m. subarcualis rectus—glossopharyngeus and vagus (IX, X); and various laryngeal, neck and shoulder muscles—vagus. Other muscles important in feeding are controlled by the abducens (VI) (m. retractor bulbi), spinal accessory (XI) (m. cucullaris), and first (XII) and second spinal nerves (mm. genioglossus, rectus cervicis, geniohyoideus medialis, geniohyoideus lateralis, and hyoglossus and other muscles of the tongue tip).

The aim of this study is to compare the topology and cytoarchitecture of the brainstem motor nuclei in salamanders that show diversity in tongue structure and in life history. A primary goal is to determine to what degree differences in these traits are reflected in the neuroanatomy of the motor nuclei of the brainstem.

MATERIALS AND METHODS

We studied salamanders belonging to five families. Species were chosen to permit appropriate phylogenetic control for interspecific comparisons. Species studied include Ambystomatidae—*Ambystoma macrodactylum* (n = 8); Dicamptodontidae—*Dicamptodon ensatus* (n = 2), *Rhyacotriton olympicus* (n = 11); Hynobiidae—*Salamandrella (Hynobius) keyserlingii* (n = 2); Plethodontidae, tribe Bolitoglossini—*Batrachoseps attenuatus* (n = 26), *Bolitoglossa subpalmata* (n = 5), *Hydromantes italicus* (n = 8), *Nototriton picadoi* (n = 1), *Thorius narisovalis* (n = 1); tribe Hemidactyliini—*Eurycea bislineata* (n = 3), *Eur. junaluska* (n = 4), *Eur. longicauda* (n = 2), *Eur. lucifuga* (n = 1), *Pseudotriton ruber* (n = 1); tribe Plethodontini—*Aneides flavipunctatus* (n = 2), *Plesatina eschscholtzii* (n = 1), *Plethodon dunni* (n = 1), *Pleth. jordani* (n = 12); subfamily Desmognathinae—*Desmognathus aeneus* (n = 3), *Des. monticola* (n = 1), *Des. ochrophaeus* (n = 5), *Des. wrighti* (n = 5); and Salamandridae—*Salamandra salamandra* (n = 6), *Salamandrina terdigitata* (n = 4), *Notophthalmus viridescens* (n = 2). Specimens used in the experiments were anesthetized both prior to surgery and, subsequently, prior to perfusion, by immersion in a 1% aqueous solution of tricaine—methanesulfonate (MS-222) for from 1 to 5 minutes depending on the size of the specimen and the species. Horseradish peroxidase (HRP, Boehringer, grade I) was applied in small pellets on the tips of micropipettes to cut stumps of selected nerves, both peripherally and near the brain, in order to fill individual nerve cells and their projections. The region in the vicinity of the tiny stump was kept as dry as possible in order to retard diffusion.

The sites of application of HRP were the following (Fig. 1). *Trigeminal nerve*: 1) ramus mandibularis at the lower jaw after exiting from the mandible and before the innervation of the m. intermandibularis, distal to innervation of the m. adductor mandibulae, and 2) ganglion (not illustrated); *abducens nerve*: immediately after exiting the brain; *facial nerve*: ramus hyomandibularis 1) between the point of bifurcation (branches to mm. depressor mandibulae and interhyoideus) and innervation of the m. interhyoideus and 2) between brain and bifurcation; *glossopharyngeus nerve*: between brain and innervation of m. subarcualis rectus; *vagus nerve*: 1) between brain and innervation of m. subarcualis rectus and 2) IX-X ganglion. We frequently used more than one site per specimen (using both right and left sides). Following standard techniques (details in Roth and Wake, '85a) we prepared frozen sections or whole mounts cleared in methyl salicylate. Some whole mounts were re-

turned to alcohol and after standard procedures embedded in Epon and cut in transverse sections at 30 μ m.

Our whole-mount technique is especially valuable for comparative studies. It is rapid and provides detailed information concerning the distribution and architecture of nuclei and of sensory projections. In many cases complete filling of all parts of nerve cells, including the finest dendrites and their terminal structures, is observed. However, there is a definite upper size limit beyond which the method loses resolution. When the diameter of the brainstem at the obex exceeds 1 mm, diaminobenzidine does not penetrate sufficiently to stain the innermost neuronal structures. The whole-mount technique can be applied to larger brains if they are hemisected prior to treatment.

RESULTS

Regional topography

The general organization of the brainstem is displayed in Figures 1 and 2. The topography is that of a generalized vertebrate, with the trigeminal nerve exiting the rostral pole of the rhombencephalon. It is followed immediately by the facial and statoacoustic nerves. Fibers of the anterior lateral-line system, when present, enter the brain at the level of these two nerves. The abducens nerve exits the extreme ventral portion of the rhombencephalon, just lateral to the midline, at a rostrocaudal level near that of the

Abbreviations

| | |
|----------|---|
| AM | adductor mandibulae muscle |
| AN | anastomosis between the facial and the glossopharyngeal nerves |
| AU | auricles of the cerebellum |
| BR | basiradialis muscle |
| CB | cerebellum |
| DM | depressor mandibulae muscle |
| DSS | descending somatosensory tract |
| FK | knee of the facialis nerve |
| FS | fasciculus solitarius |
| GG | genioglossus muscle |
| GHL | geniohyoideus lateralis muscle |
| GHM | geniohyoideus medialis muscle |
| GV | ganglion of the trigeminal nerve |
| HG | hyoglossus muscle |
| IH | interhyoideus muscle |
| IM | intermandibularis muscle |
| IR | interradialis muscle |
| MESVD | descending tract of the mesencephalic trigeminal nucleus |
| MESVE | exiting tract of the mesencephalic trigeminal nucleus |
| LL | anterior lateral line nerve projections |
| RG | rhombencephalic groove |
| TO | tectum opticum |
| V | trigeminal nerve/nucleus |
| Va | anterior portion of the trigeminal nucleus |
| Vp | posterior portion of the trigeminal nucleus |
| VI | abducens nerve/nucleus |
| VIacc | accessory nucleus of the abducens nerve |
| VII | facialis nerve/nucleus |
| VIIa | anterior portion of the facialis nucleus |
| VIIp | posterior portion of the facialis nucleus |
| VII*/VII | separate motor root of the ramus hyomandibularis of the |
| hm | facialis nerve |
| IX | glossopharyngeus nerve/nucleus |
| X | vagus nerve/nucleus |
| Xm | motor root of the vagus nerve |
| XPS | parasympathetic portion of the vagus nucleus |
| XSAR | root and portion of the vagus nucleus supplying the subarcualis rectus muscle |
| XI | accessorius spinalis nerve/nucleus |
| 1SP | first spinal nerve/nucleus |
| 2SP | second spinal nerve/nucleus |
| 2SPm | motor root of the second spinal nerve |

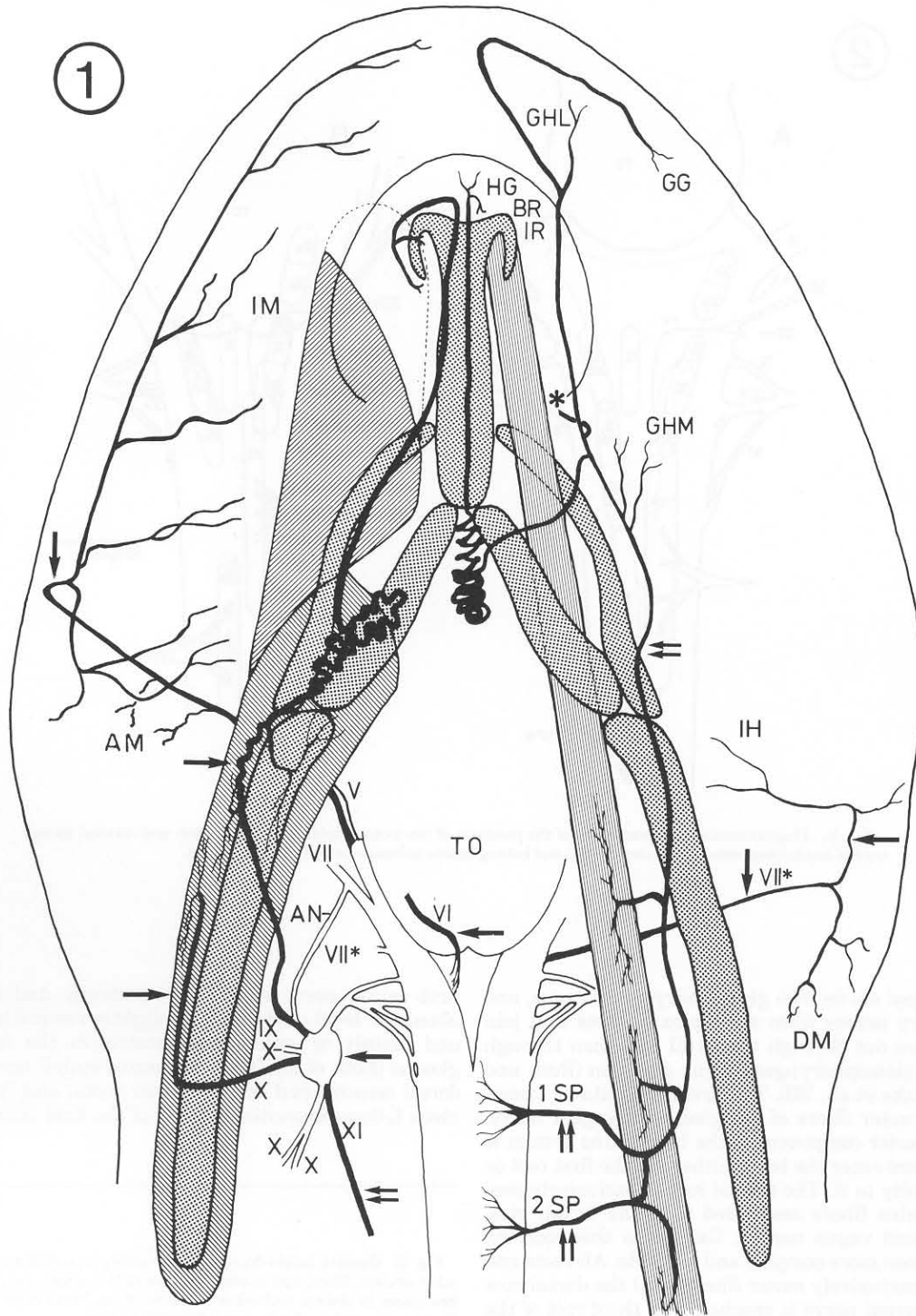


Fig. 1. Schematic diagram of the innervation of the tongue and associated musculature in a plethodontid salamander, here *Batrachoseps attenuatus*. The figure shows the lower jaw with the tongue skeleton (stippled area), the tongue protractor muscle, subarcualis rectus (left side; the two parts of this muscle are indicated by different hatching), the tongue retractor muscle, rectus cervicis profundus (right side, parallel-lined band), the roots and course of nerves V (ramus mandibularis), VI (root only), IX, X, and XI on the left side, of nerves VII (ramus hyomandibularis), first spinal and second spinal on the right, and the outlines of the tongue pad, brain-

stem, and cervical spinal cord. An asterisk indicates the site of the supra-peduncularis muscle of plethodontid salamanders. The diagram represents a combination of the dorsal and ventral aspects, and left and right halves, of the brain. The ganglia and branches of nerves V and VII unrelated to feeding are not shown for the sake of clarity of illustration. Single arrows indicate sites of nerve sectioning and labeling with HRP for the present study. Double arrows are sites of nerve sectioning and labeling used in the following paper (Wake et al., '88).

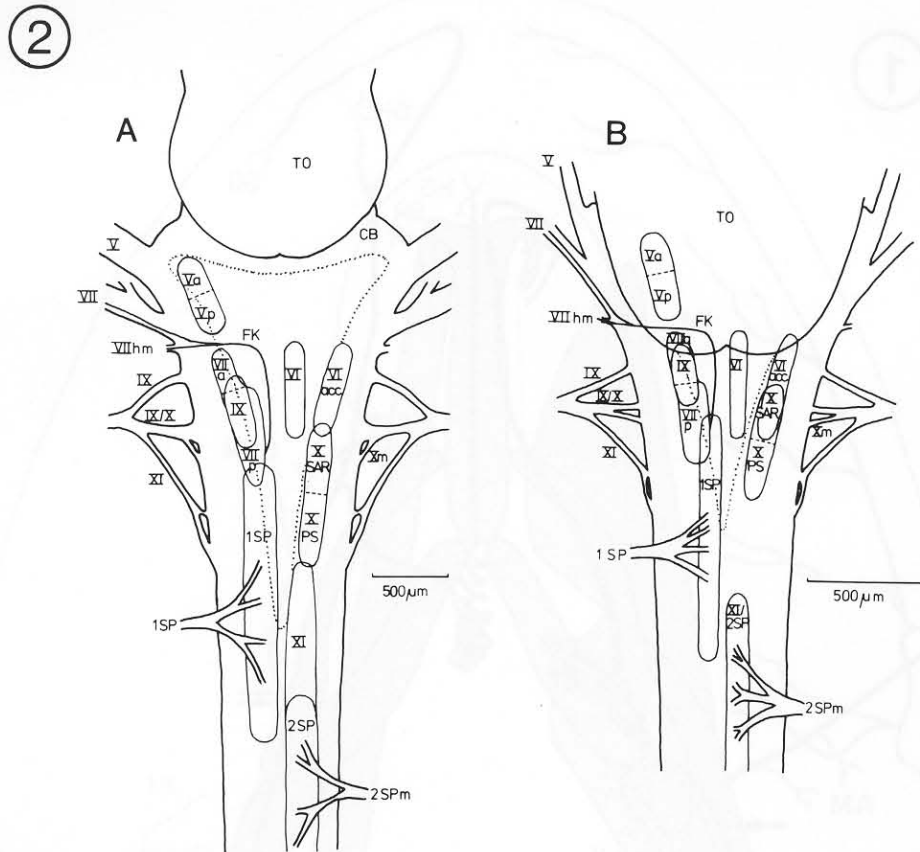


Fig. 2. Diagrammatic representations of the positions of the motor nuclei in the brainstem and cervical spinal cord of nonbolitoglossine (A, *Salamandra*) and bolitoglossine salamanders (B, *Batrachoseps*).

glossopharyngeal nerve. The glossopharyngeal, vagus, and spinal accessory nerves form a complex of roots that join together to pass out through the skull and then through the combined glossopharyngeal-vagus ganglion (Roth and Wake, '85a; Wake et al., '83). The first root contains viscerosensory and motor fibers of the glossopharyngeal nerve. When the posterior component of the lateral-line system is present, its fibers enter the brain either via the first root or in close proximity to it. The second root is exclusively sensory and contains fibers associated with the facial, glossopharyngeal, and vagus nerves. Caudal to this root the situation becomes more complex and variable. All roots and rootlets carry exclusively motor fibers until the dorsal root of the second spinal nerve is reached. The third root of the complex, often situated in close proximity to the second one, contains exclusively motor fibers of the vagus, and the fourth (usually the last) contains fibers of the accessorius. The third and fourth roots exit from the ventrolateral surface of the brainstem, in front of the obex. Between the third and fourth roots there may be a number of tiny rootlets, as many as four, and rarely tiny rootlets are found caudad to the fourth root. The most posterior rootlet that we have seen (in a larval *Pseudotriton ruber*) was at the level of the first spinal nerve, just in front of the obex. The

first spinal nerve exits more ventrally and medially at about the level of the obex or slightly rostrad to that point and mainly or exclusively constitutes the ramus hypoglossus (Roth et al., '84). The second spinal nerve has both dorsal sensory and ventral motor roots, and its motor nucleus follows immediately that of the first spinal. The sec-

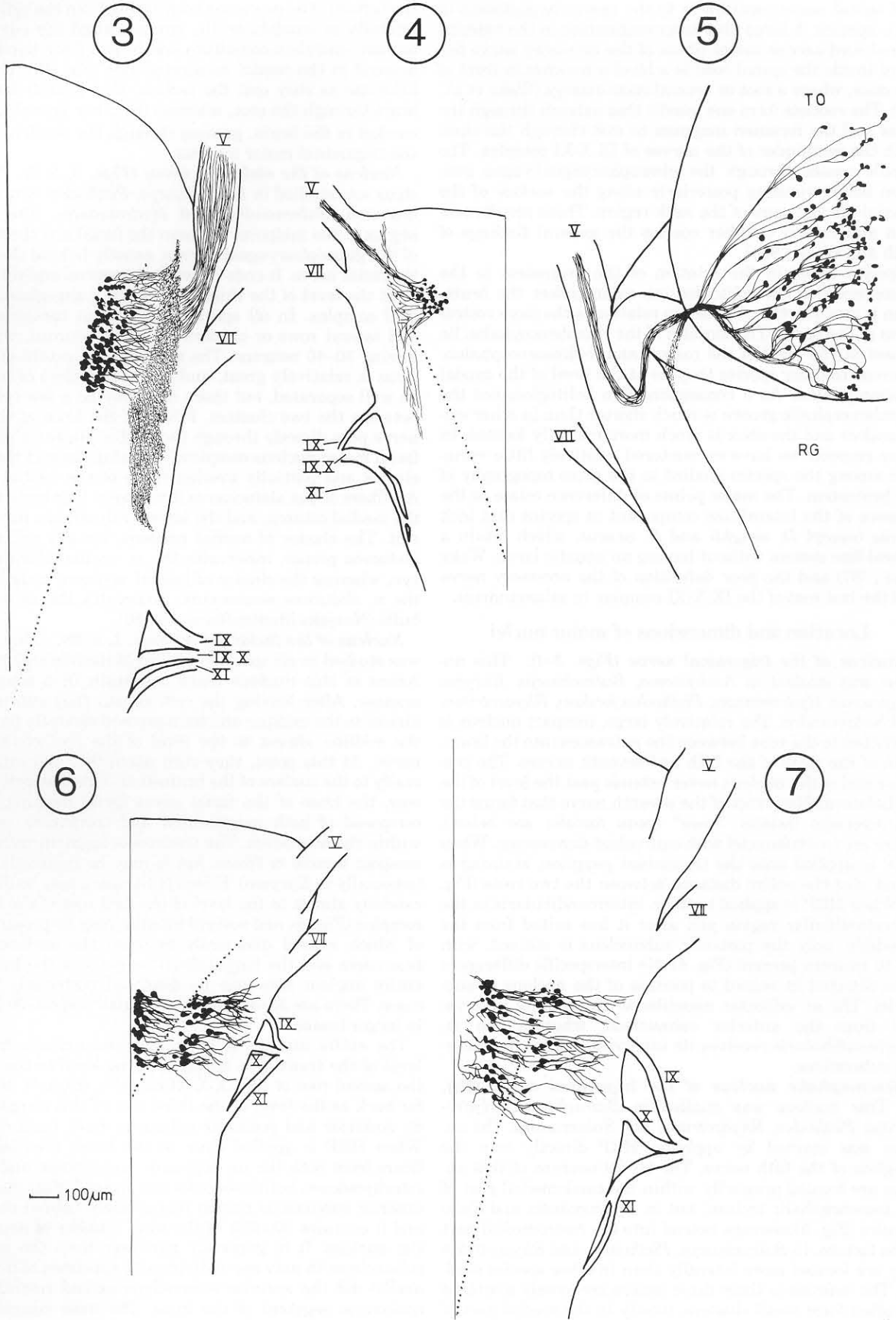
Fig. 3. Camera lucida drawing of the entire trigeminal nucleus in *Plethodon jordani*. Here, and in other figures in this paper, only one-half of the brainstem is shown, and other portions of the brain have been removed. Roman numerals indicate roots of cranial nerves.

Fig. 4. Camera lucida drawing of the posterior subnucleus of the trigeminus in *Batrachoseps attenuatus*.

Fig. 5. Camera lucida drawing of the trigeminal mesencephalic nucleus of *Plethodon jordani*, viewed dorsally.

Fig. 6. Camera lucida drawing of the entire abducens nucleus of *Batrachoseps attenuatus*.

Fig. 7. Camera lucida drawing of the entire abducens nucleus of *Salamandra salamandra*.



and spinal nerve contributes to the ramus hypoglossus in some species. A large fiber tract originating in the anterior spinal cord carries motor fibers of the accessory nerve forward inside the spinal cord to a level somewhat in front of the obex, where a root or several roots emerge (Wake et al., '88). The rootlets form one bundle that extends through the atlas and the foramen magnum to exit through the skull with the remainder of the nerves of IX-X-XI complex. The bundle passes through the glossopharyngeal-vagus ganglion before running posteriorly along the surface of the epaxial musculature of the neck region. These results confirm and extend to other species the general findings of Roth and Wake ('85a).

Species differ in the relation of the brainstem to the mesencephalon. In bolitoglossine salamanders the brainstem is much farther forward in relation to the more rostral parts of the brain. The auricles of the rhombencephalon lie almost at the level of the rostral and midmesencephalon, whereas in other species they lie at the level of the caudal mesencephalon. As a consequence, in bolitoglossines the rhombencephalic groove is much shorter than in other salamanders and the obex is much more rostrally located. In other respects we have encountered relatively little variation among the species studied in the gross topography of the brainstem. The major points of difference relate to the absence of the lateral-line component in species that lack larvae (except *D. wrighti* and *D. aeneus*, which retain a lateral-line system without having an aquatic larva, Wake et al., '87) and the poor definition of the accessory nerve and the last root of the IX-X-XI complex in salamandrids.

Location and dimensions of motor nuclei

Nucleus of the trigeminal nerve (Figs. 2-4). This nucleus was studied in *Ambystoma*, *Batrachoseps*, *Eurycea longicauda*, *Hydromantes*, *Plethodon jordani*, *Rhyacotriton*, and *Salamandra*. The relatively large, compact nucleus is restricted to the zone between the entrances into the brainstem of the roots of the fifth and seventh nerves. The posterior end of the nucleus never extends past the level of the mediolateral fiber tract of the seventh nerve that forms the characteristic facialis "knee" (*genu facialis*, see below). There are two subnuclei with equivalent dimensions. When HRP is applied onto the trigeminal ganglion, staining is found over the entire distance between the two roots (Fig. 3). When HRP is applied to the r. intermandibularis in the intermandibular region just after it has exited from the mandible, only the posterior subnucleus is stained, with 25-40 neurons present (Fig. 4). No interspecific differences were detected in regard to position of the nucleus or subnuclei. The m. adductor mandibulae receives its innervation from the anterior subnucleus, whereas the m. intermandibularis receives its innervation from the posterior subnucleus.

Mesencephalic nucleus of the trigeminal nerve (Fig. 5). This nucleus was studied in *Batrachoseps*, *Hydromantes*, *Plethodon*, *Rhyacotriton*, and *Salamandra*. The nucleus was stained by applying HRP directly into the ganglion of the fifth nerve. The 60-90 neurons of this nucleus are located primarily within the caudomedial part of the mesencephalic tectum, but in *Hydromantes* and *Salamandra* (Fig. 5) neurons extend into the rostromedial part of the tectum. In *Batrachoseps*, *Plethodon*, and *Rhyacotriton* they are located more laterally than in other species studied. The neurons in these three genera are loosely scattered but often form small clusters, mostly in the medial part of

the tectum. The processes originating from the cells extend laterally or caudolaterally, curve around the edge of the tectum, and then constitute one to two fiber bundles that descend in the caudal mesencephalon (Fig. 16). The fibers bifurcate as they exit the tectum. One branch leaves the brain through the root, whereas the other branch descends caudad in the brain, passing through the dendritic field of the trigeminal motor nucleus.

Nucleus of the abducens nerve (Figs. 2, 6, 7). This nucleus was studied in *Batrachoseps*, *Plethodon jordani*, *Rhyacotriton*, *Salamandra*, and *Hydromantes*. The nucleus begins at the midpoint between the facial and the first root of the glossopharyngeal nerves, exactly behind the knee of the facial nerve. It ends between the second and third roots, or at the level of the third root, of the vagus-glossopharyngeal complex. In all species the nucleus contains medial and lateral rows or clusters of motor neurons, with each having 30-40 neurons. The mediolateral extent of the nucleus is relatively great, and the two clusters of cells may be well separated, but there also may be a few cells lying between the two clusters. Fibers of the knee of the facial nerve pass directly through the medial cluster. Cells of the facial motor nucleus completely overlap those of the lateral cluster and partially overlap those of the medial cluster. All fibers of the abducens exit via up to four rootlets below the medial column, and the lateral column has no separate exit. The cluster of medial neurons, usually called the n. abducens proper, innervates the m. rectus lateralis of the eye, whereas the cluster of lateral neurons, usually called the n. abducens accessorius, innervates the m. retractor bulbi (Naujoks-Manteuffel et al., '86).

Nucleus of the facial nerve (Figs. 2, 8-10). This nucleus was studied in all species listed in Materials and Methods. Axons of this nucleus leave the brain in a conspicuous manner. After leaving the cell somata they run medially almost to the midline and then proceed rostrally parallel to the midline almost to the level of the root of the facial nerve. At this point, they turn about 90° and extend laterally to the surface of the brainstem. This distinctive pathway, the knee of the facial nerve (*genu facialis*), is thus composed of both longitudinal and transverse segments within the brainstem. The transverse segment usually is a compact bundle of fibers, but it may be relatively diffuse (especially in *Eurycea*). Fibers of the knee may be displaced caudally almost to the level of the first root of the IX-X-XI complex (Fig. 8), and several bundles may be present, some of which extend diagonally between the surface of the brainstem and the longitudinal segment of the knee. The entire nucleus also may be displaced posteriorly in such cases. There are 35-45 neurons in small and 60-70 neurons in larger brains.

The entire nucleus is very long and extends from the level of the transverse segment of the knee to the level of the second root of the IX-X-XI complex (Figs. 9, 10), or as far back as the level of the third root of this complex (Fig. 8). Anterior and posterior subnuclei have been detected. When HRP is applied close to the brain (i.e., including fibers from both the m. depressor mandibulae and the m. interhyoideus), both subnuclei are stained (Figs. 8, 9). The anterior subnucleus begins immediately behind the knee, and it contains 30-40% of the total number of neurons in the nucleus. It is generally narrower than the posterior subnucleus. In only one individual (a specimen of *Salamandrella*) did the anterior subnucleus extend rostral to the transverse segment of the knee. The most rostral axons

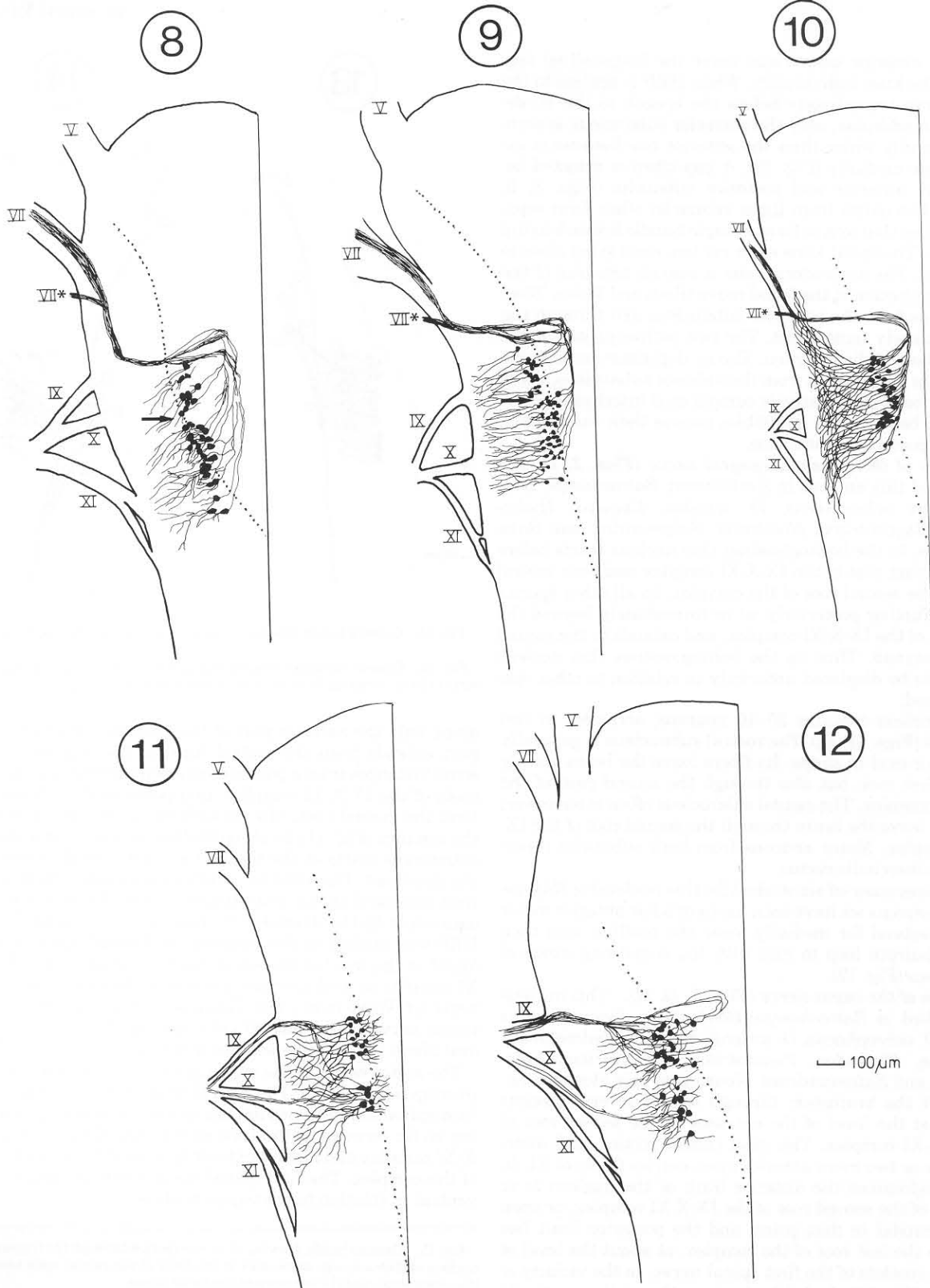


Fig. 8. Camera lucida drawing of the entire facial nucleus in *Rhyacotriton olympicus*. Arrow indicates the level of separation of the anterior and posterior subnuclei.

Fig. 9. Camera lucida drawing of the entire facial nucleus in *Salamandra salamandra*. Arrow indicates the level of separation of the anterior and posterior subnuclei.

Fig. 10. Camera lucida drawing of the posterior subnucleus of the facial nucleus in *Nototriton picadoi*.

Fig. 11. Camera lucida drawing of the glossopharyngeal nucleus in *Plethodon jordani*, showing the division into two subnuclei.

Fig. 12. Camera lucida drawing of the entire glossopharyngeal nucleus in *Rhyacotriton olympicus*. Note the hairpinlike route of some of the anterior fiber tracts.

from the anterior subnucleus enter the longitudinal segment of the knee individually. When HRP is applied to the facial nerve immediately before the branch to the m. depressor mandibulae, only the posterior subnucleus is seen. It is generally wider than the anterior one because it extends more medially (Fig. 10). A gap often is detected between the anterior and posterior subnuclei (Figs. 8, 9, arrows). The axons from these subnuclei often form separate bundles that join to form a single bundle before leaving the brain. The facial knee exits via two roots lying close to each other. The anterodorsal one is also an entrance of the sensory projection of the facial nerve (Roth and Wake, '85a). Most axons from the posterior subnucleus exit through the ventral, purely motor, root. The two pathways join at the level of the facialis ganglion. The m. depressor mandibulae receives its innervation from the anterior subnucleus, while the muscles of the relatively complicated interhyoideus series lying between the mandibles receive their innervation from the posterior subnucleus.

Nucleus of the glossopharyngeal nerve (Figs. 2, 11, 12). We studied this nucleus in *Ambystoma*, *Batrachoseps*, *Desmognathus ochrophaeus*, *D. wrighti*, *Eurycea*, *Hydromantes*, *Rhyacotriton*, *Nototriton*, *Salamandra*, and *Salamandrina*. In the bolitoglossines this nucleus starts before or at the first root of the IX-X-XI complex and ends rostral to or at the second root of the complex. In all other species it starts further posteriorly, at or immediately beyond the first root of the IX-X-XI complex, and extends to the second root or beyond. Thus in the bolitoglossines this nucleus appears to be displaced anteriorly in relation to other species studied.

This nucleus contains 25–40 neurons, arranged in two subnuclei (Figs. 11, 12). The rostral subnucleus is generally rounded or oval in shape. Its fibers leave the brain mainly via the first root, but also through the second root, of the IX-X-XI complex. The caudal subnucleus often is narrower; its fibers leave the brain through the second root of the IX-X-XI complex. Motor neurons from both subnuclei innervate m. subarcualis rectus.

In one specimen (of six studied for this nucleus) of *Rhyacotriton olympicus* we have seen axons of a few anterior motor neurons extend far medially, near the midline, and then make a hairpin loop to exit with the remaining axons of the nucleus (Fig. 12).

Nucleus of the vagus nerve (Figs. 2, 13, 14). This nucleus was studied in *Batrachoseps*, *Bolitoglossa*, *Desmognathus aeneus*, *D. ochrophaeus*, *D. wrighti*, *Eurycea*, *Hydromantes*, *Nototriton*, *Plethodon*, *Pseudotriton*, *Rhyacotriton*, *Salamandra*, and *Salamandrina*. Neurons of this elongate nucleus exit the brainstem through one to several rootlets starting at the level of the entrance of the second root of the IX-X-XI complex. The most caudal rootlet, and sometimes one or two more anterior ones, carries fibers of XI. In nonbolitoglossines the anterior limit of the nucleus is at the level of the second root of the IX-X-XI complex, or even slightly caudal to that point, and the posterior limit lies caudal to the last root of the complex, at about the level of the main rootlets of the first spinal nerve, in the vicinity of the obex (Fig. 13). In bolitoglossines the nucleus extends farther forward, to about the level of the first root of the IX-X-XI complex, and also ends farther forward, at a point slightly rostral to the last root of the complex.

Two subnuclei of the vagus nerve were found in all species studied. When HRP was applied to the branch of the nerve innervating the m. subarcualis rectus in bolitogloss-

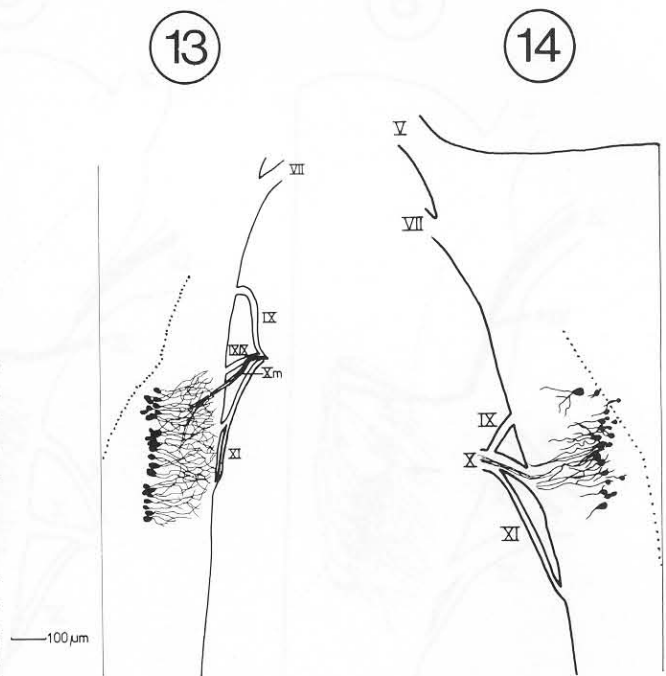


Fig. 13. Camera lucida drawing of the entire vagus nucleus in *Eurycea*.

Fig. 14. Camera lucida drawing of that portion of the vagus nucleus that serves the m. subarcualis rectus (SAR) in *Batrachoseps attenuatus*.

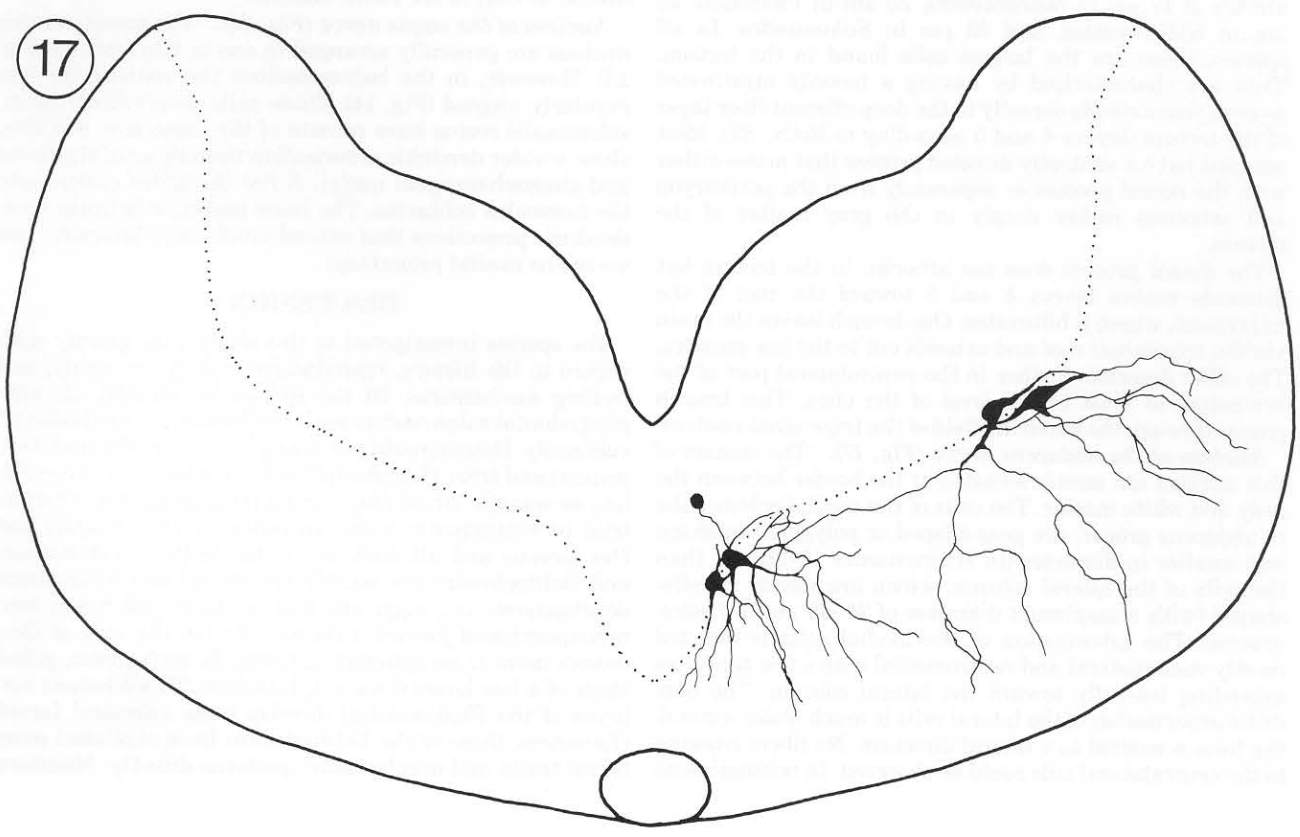
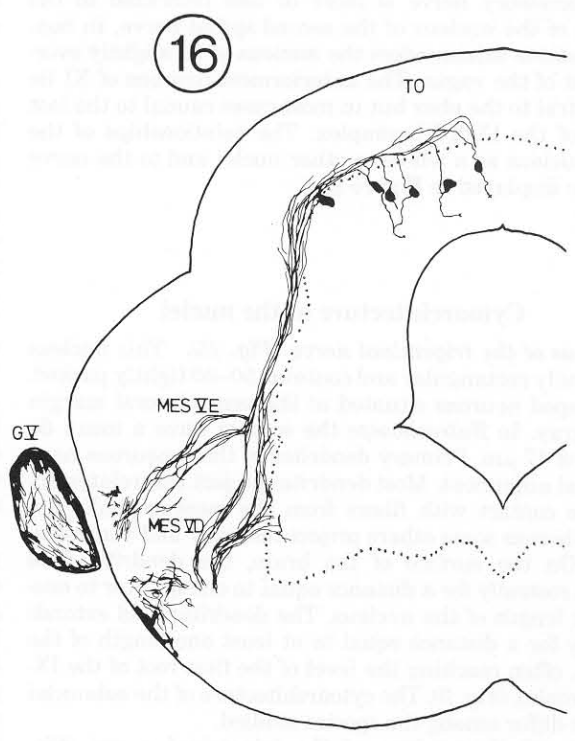
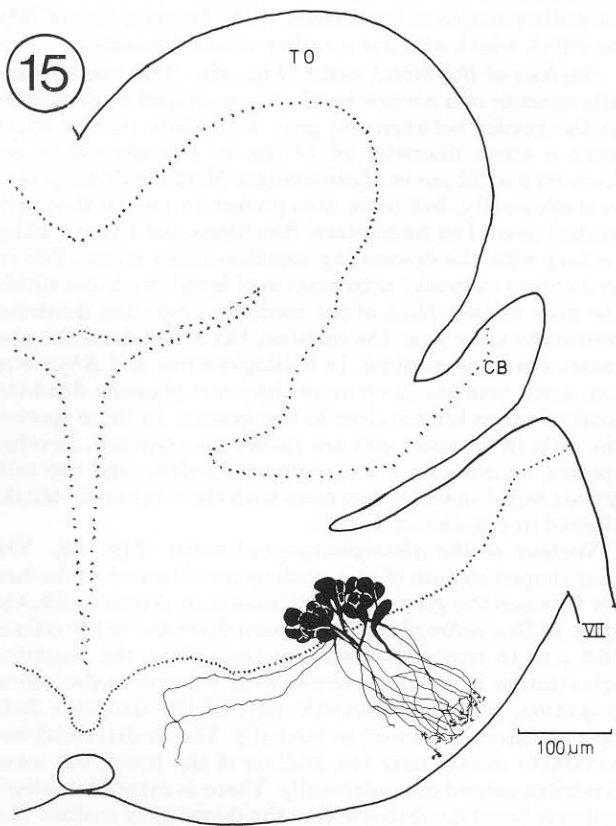
sines, only the anterior part of the nucleus is stained. This part extends from the rostral limit of the nucleus, or in some instances from a position between the first and second roots of the IX-X-XI complex, to a position 20–150 μm behind the second root, always well before the third root of the complex (Fig. 14). In all nonbolitoglossines, the anterior subnucleus starts at the second root and extends almost to the third root. The anterior subnucleus includes 20–30 neurons arranged in an oval-shaped cluster having a width equivalent to the diameter of three or four somata. When HRP was applied to the ganglion, additional staining was found at the level of the set of caudal rootlets of the IX-X-XI complex as well as in the nucleus of the spinal accessory nerve (cf. Wake et al., '88). This posterior subnucleus of the vagus nerve has about 30 cells arranged in an elongate oval about two to three somata in width.

The motor nuclei of the vagus and of the first spinal nerve overlap considerably. The rostral limit of the nucleus of the first spinal nerve varies among species, sometimes extending as far forward as the level of the second root of the IX-X-XI complex and always extending rostral to the last roots of the complex. The first spinal nerve lies both medial and ventral in relation to the vagus nucleus.

Fig. 15. Camera lucida drawing of a cross section through the trigeminal nucleus of *Batrachoseps attenuatus* at the level of the caudal optic tectum, the cerebellum, and the entrance of the facial nerve.

Fig. 16. Camera lucida drawing of a cross section through the optic tectum and the rostral rhombencephalon of *Plethodon jordani*, showing the trigeminal mesencephalic nucleus and its descending fibers.

Fig. 17. Camera lucida drawing of a cross section through the brainstem of *Hydromantes italicus*, showing the abducens (medial) and accessory abducens (lateral) subnuclei.



Whereas in bolitoglossine salamanders the nucleus of the spinal accessory nerve is more or less restricted to the position of the nucleus of the second spinal nerve, in non-bolitoglossine salamanders the nucleus of XI slightly overlaps that of the vagus. The anteriormost neurons of XI lie well rostral to the obex but in most cases caudal to the last rootlet of the IX-X-XI complex. The relationships of the vagus nucleus as a whole to other nuclei and to the nerve roots are displayed in Figure 2.

Cytoarchitecture of the nuclei

Nucleus of the trigeminal nerve (Fig. 15). This nucleus is generally rectangular and contains 50–80 tightly packed, pear-shaped neurons situated at the ventrolateral margin of the gray. In *Batrachoseps* the somata have a mean diameter of 17 μm . Primary dendrites of these neurons have a parallel alignment. Most dendrites project ventrolaterally to make contact with fibers from the mesencephalic nucleus, whereas some others project medially and ventromedially. On the surface of the brain, the dendritic field extends rostrally for a distance equal to one-quarter to one-half the length of the nucleus. The dendritic field extends caudally for a distance equal to at least one length of the nucleus, often reaching the level of the first root of the IX-X-XI complex (Fig. 3). The cytoarchitecture of the subnuclei does not differ among the species studied.

Mesencephalic nucleus of the trigeminal nerve (Fig. 16). The neurons of this nucleus are found throughout the tectal gray matter, although the majority of them are found in the upper half (layer 6 according to Roth, '87). The somata are rounded or oval-shaped, with a maximum diameter of 17 μm in *Batrachoseps*, 20 μm in *Plethodon*, 28 μm in *Hydromantes*, and 33 μm in *Salamandra*. In all species, these are the largest cells found in the tectum. They are characterized by having a heavily myelinated process that extends dorsally to the deep efferent fiber layer of the tectum (layers 4 and 5 according to Roth, '87). Most neurons have a ventrally directed process that arises either with the dorsal process or separately from the perikaryon and arborizes rather deeply in the gray matter of the tectum.

The dorsal process does not arborize in the tectum but descends within layers 4 and 5 toward the root of the trigeminal, where it bifurcates. One branch leaves the brain via the trigeminal root and extends out to the jaw muscles. The other descends further in the ventrolateral part of the brainstem at least to the level of the obex. This branch passes through the dendritic field of the trigeminal nucleus.

Nucleus of the abducens nerve (Fig. 17). The somata of this nucleus are mostly situated at the border between the gray and white matter. The cells of the medial column, the n. abducens proper, are pear-shaped or polygonal in shape and smaller in diameter (in *Hydromantes* 15–20 μm) than the cells of the lateral column, which are mostly spindle-shaped (with a maximum diameter of 25–40 μm in *Hydromantes*). The arborization of the medial cells is directed mostly ventrolaterally and ventromedial with a few dendrites extending laterally toward the lateral column. The dendritic arborization of the lateral cells is much wider, extending from a ventral to a lateral direction. No fibers crossing to the contralateral side could be observed. In bolitoglossine

salamanders, the arborization is generally wider than in nonbolitoglossine salamanders, with the exception of *Rhyacotriton*, which also has a rather wide arborization.

Nucleus of the facial nerve (Fig. 18). The nucleus usually consists of a narrow band or pear-shaped cells situated at the border between the gray and white matter which have a mean diameter of 17 μm in *Desmognathus* and *Eurycea* and 22 μm in *Hydromantes*. Most dendrites project ventrolaterally, but some also project in medial-to-ventromedial as well as dorsolateral directions, the latter making contact with the descending somatosensory tracts. The somata show extensive arborization of basal dendrites within the gray matter. Most of the medially projecting dendrites terminate at or near the midline, but a few dendritic processes cross the midline. In bolitoglossines and *Rhyacotriton*, some neurons have more than one primary dendrite, most of which branch close to the somata. In these species, the cells in all subnuclei are rather unorganized. In other species, neurons have one primary dendrite and the cells are arranged in one to two rows with their dendritic trunks aligned in parallel (cf. Fig. 9).

Nucleus of the glossopharyngeal nerve (Fig. 19). The pear-shaped somata of this nucleus are situated at the border between the gray and white matter or deeper inside the gray. In *Des. ochrophaeus*, the mean diameter of the cells is 16.5 μm . In nonbolitoglossine salamanders, the dendritic arborization is usually narrow, with a major ventrolateral projection, but a considerable part of the dendritic field extends laterally as well as medially. The medial dendrites terminate mostly near the midline of the brain, but some dendrites extend contralaterally. There is extensive arborization of basal dendrites within the dorsal gray matter. The pattern of variation among species regarding the arrangement of cells and the pattern of dendritic arborization is similar to that in the facial nucleus.

Nucleus of the vagus nerve (Fig. 20). The somata of this nucleus are generally arranged in one or two rows (cf. Fig. 13). However, in the bolitoglossines the somata are less regularly aligned (Fig. 14). Those cells innervating the m. subarcualis rectus have somata of the same size, but they show a wider dendritic arborization than those of the facial and glossopharyngeal nuclei. A few dendrites extend into the fasciculus solitarius. The more posterior neurons have dendritic projections that extend much more laterally, and we see no medial projections.

DISCUSSION

The species investigated in this study vary greatly with regard to life history, reproductive biology, ontogeny, and feeding mechanisms. Of the species we studied, all nonplethodontid salamanders and members of the plethodontid subfamily Desmognathinae (except *Des. wrighti* and *Des. aeneus*) and tribe Hemidactyliini have a biphasic life cycle, i.e., an aquatic larval stage and a postmetamorphic terrestrial or semiaquatic stage. In contrast, *Des. wrighti* and *Des. aeneus* and all members of the tribes Plethodontini and Bolitoglossini are strictly terrestrial and have direct development; i.e., eggs are laid on land and hatch into metamorphosed juveniles (Wake '66). (In the case of *Des. aeneus* there is an ephemeral, normally nonaquatic, gilled stage of a few hours duration; Harrison, '67.) Whereas embryos of the Plethodontini develop some ancestral larval characters, those of the Bolitoglossini have abolished most larval traits and develop adult patterns directly. Members

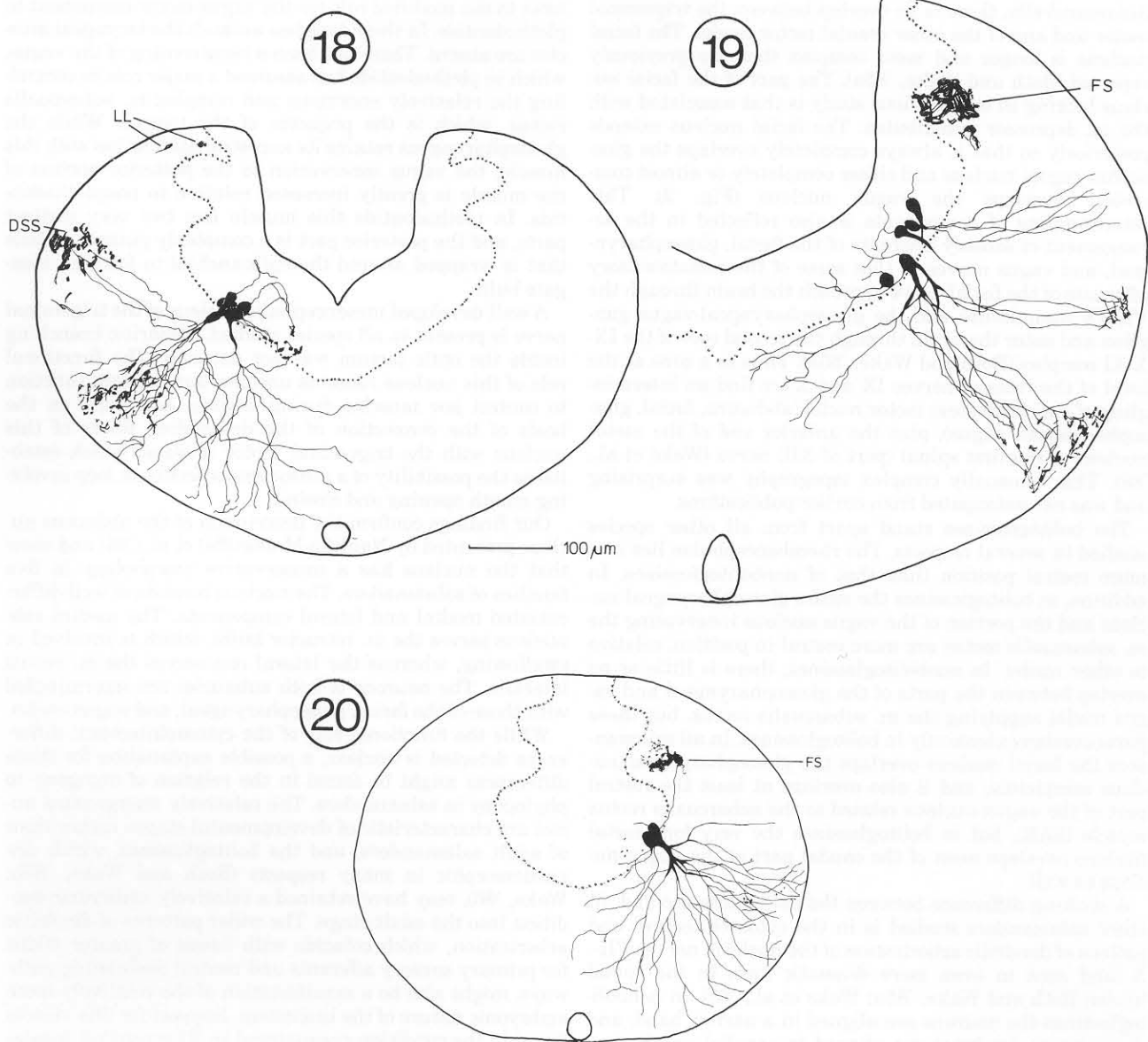


Fig. 18. Camera lucida drawing through the brainstem at the level of the posterior part of the facial nucleus in *Eurycea bislineata*.

Fig. 19. Camera lucida drawing through the brainstem at the level of the glossopharyngeal nucleus in *Desmognathus ochrophaeus*.

Fig. 20. Camera lucida drawing through the brainstem at the level of the vagus nucleus in *Eurycea bislineata*.

of the families Ambystomatidae, Dicamptodontidae, and Hynobiidae show little functional specialization in feeding and retain many ancestral traits in their musculoskeletal anatomy. The members of the family of Plethodontidae, in contrast, show a broad range of feeding modes, from short and medium-range flipping tongues in *Desmognathinae* and *Plethodontini*, to free, projectile tongues of medium and long range in *Hemidactyliini* and *Bolitoglossini* (Lombard and Wake, '76, '77, '86). Loss of lungs has important implications for the evolution of highly specialized tongues (Roth and Wake, '85b; Wake, '82), so we included lungless repre-

sentatives of the Dicamptodontidae (*Rhyacotriton*) and Salamandridae (*Salamandrina*) in order to have a direct comparison with the exclusively lungless plethodontids.

We found surprisingly little differentiation of the brainstem among these diverse species. The structure of the motor and mesencephalic nuclei of the trigeminal nerve appears to be strongly conserved in salamanders, and no major differences were detected. The trigeminal motor nucleus is followed immediately by the broadly overlapping abducens and facial nuclei, both of which completely overlap the glossopharyngeal nucleus. With the exception of

Salamandrella, there is no overlap between the trigeminal motor and any of the other cranial motor nuclei. The facial nucleus is longer and more complex than we previously reported (Roth and Wake, '85a). The part of the facial nucleus lacking in our previous study is that associated with the m. depressor mandibulae. The facial nucleus extends posteriorly so that it always completely overlaps the glossopharyngeal nucleus and either completely or almost completely overlaps the vagus nucleus (Fig. 2). This intermingling of components is also reflected in the arrangement of sensory afferents of the facial, glossopharyngeal, and vagus nerves in that some of the somatosensory afferents of the facial nerve approach the brain through the VII-IX commissure and the glossopharyngeal-vagus ganglion and enter the brain through the second root of the IX-X-XI complex (Roth and Wake, '85a). Thus in a zone at the level of the roots of nerves IX and X we find an intermingling of four brainstem motor nuclei (abducens, facial, glossopharyngeal, vagus), plus the anterior end of the motor nucleus of the first spinal (part of XII) nerve (Wake et al., '88). This unusually complex topography was surprising and was not anticipated from earlier publications.

The bolitoglossines stand apart from all other species studied in several respects. The rhombencephalon lies in a more rostral position than that of nonbolitoglossines. In addition, in bolitoglossines the entire glossopharyngeal nucleus and the portion of the vagus nucleus innervating the m. subarcualis rectus are more rostral in position, relative to other nuclei. In nonbolitoglossines, there is little or no overlap between the parts of the glossopharyngeal and vagus nuclei supplying the m. subarcualis rectus, but these parts overlap extensively in bolitoglossines. In all salamanders the facial nucleus overlaps the glossopharyngeal nucleus completely, and it also overlaps at least the rostral part of the vagus nucleus related to the subarcualis rectus muscle (SAR), but in bolitoglossines the very long facial nucleus overlaps most of the caudal part of the vagus nucleus as well.

A striking difference between the bolitoglossines and all other salamanders studied is in the cytoarchitecture and pattern of dendritic arborization of the nuclei of nerves VII-X (and seen in even more dramatic form in the spinal nuclei; Roth and Wake, '85a; Wake et al., '88). In nonbolitoglossines the neurons are aligned in a narrow band, and the primary dendrites are aligned in parallel and have a pattern of narrow arborization. In contrast, the nuclei of bolitoglossines are wider and give the appearance of less structural organization. The somata are less orderly in arrangement, and the primary dendrites are not as parallel in alignment. Many cells have more than one primary dendrite. Arborization is wider, sometimes much wider, and starts closer to the soma than in nonbolitoglossines. *Rhyacotriton* is intermediate in some respects between the two patterns summarized above.

The differences described above may have functional significance. The topological coincidence of that part of the facial nucleus that controls the m. interhyoideus complex with the glossopharyngeal nucleus and that part of the vagus nucleus that controls m. subarcualis rectus may be associated with synchronization of the muscles associated with the feeding act in the highly specialized bolitoglossines. The close packing of cells in these overlapping nuclei provides opportunities for direct coupling among dendrites and somata. Another functionally significant change re-

lates to the modified role for the vagus motor component in plethodontids. In these lungless animals the laryngeal muscles are absent. There has been a repatterning of the vagus, which in plethodontids has assumed a major role in controlling the relatively enormous and complex m. subarcualis rectus, which is the projector of the tongue. While the glossopharyngeus retains its ancestral association with this muscle, the vagus innervation to the posterior portion of the muscle is greatly increased relative to nonplethodontids. In plethodontids this muscle has two very distinct parts, and the posterior part is a complexly pinnate muscle that is wrapped around the epibranchial to form an elongate bulb.

A well-developed mesencephalic nucleus of the trigeminal nerve is present in all species studied. Dendritic branching inside the optic tectum was not detected. The functional role of this nucleus remains unclear, but it might function to control jaw muscles during feeding, especially on the basis of the connection of the descending fibers of this nucleus with the trigeminal motor nucleus, which establishes the possibility of a sensorimotor feedback loop involving mouth opening and closing.

Our findings confirm the description of the abducens nucleus presented by Naujoks-Manteuffel et al. ('86) and show that the nucleus has a conservative morphology in five families of salamanders. The nucleus consists of well-differentiated medial and lateral components. The medial subnucleus serves the m. retractor bulbi, which is involved in swallowing, whereas the lateral one serves the m. rectus lateralis. The neurons of both subnuclei are intermingled with those of the facial, glossopharyngeal, and vagus nuclei.

While the functional role of the cytoarchitectural differences detected is unclear, a possible explanation for these differences might be found in the relation of ontogeny to phylogeny in salamanders. The relatively unorganized nuclei are characteristic of developmental stages rather than of adult salamanders, and the bolitoglossines, which are paedomorphic in many respects (Roth and Wake, '85b; Wake, '66), may have retained a relatively embryonic condition into the adult stage. The wider patterns of dendritic arborization, which coincide with bands of greater width for primary sensory afferents and central descending pathways, might also be a manifestation of the relatively more embryonic nature of the brainstem. Support for this view is found in the condition encountered in *Rhyacotriton*, a salamander that not only shows wide dendritic arborization but also is affected by paedomorphosis (Wake, '80). No other salamanders we have studied show such a pattern. If paedomorphosis has global effects on bolitoglossine morphology (Alberch and Alberch, '81), it would be expected that its effects would extend to the cellular as well as to the gross morphological level of organization.

Previous workers have differed in their interpretation of the structure of the trigeminal nucleus in salamanders, but none used tracing techniques. Herrick ('30) found that the trigeminal nucleus had two distinct parts in *Necturus*, but Opdam and Nieuwenhuys ('76) failed to find a subdivision in *Ambystoma*. We confirmed the findings of Herrick. In Opdam and Nieuwenhuys ('76), the facial nucleus in *Ambystoma* was illustrated as consisting of two discontinuous parts, the more posterior continuous with the glossopharyngeal nucleus, but there was no elaboration of this point in the text, except a statement that they could not confirm the existence of a pars caudalis to the facial nucleus, as Herrick

('30) and Leghissa ('49) had reported. In contrast to all previous work, we find the facial nucleus to be subdivided but continuous and to completely overlap the glossopharyngeal nucleus. Our distinction between the facial and the glossopharyngeal and vagus nuclei in the area of overlap is based on the different axonal pathways inside the brain, different exits, and different target organs. Previous authors have not described a kneelike pathway (*genu facialis*) for the axonal components of the facial nucleus inside the brainstem of salamanders. All motor components of the facial nucleus send their axons via the knee, whereas all glossopharyngeal and vagus motor components send their axons directly via the first and second roots of the complex that passes through the combined glossopharyngeal-vagus ganglion. We found a hairpinlike medial loop in the anterior part of the glossopharyngeal nucleus in one specimen of *Rhyacotriton*, but apart from this case there is no kneelike pathway for any but the facial nucleus.

A number of papers (Matesz and Székely, '77, '78; Matsushima et al., '86; Nieuwenhuys and Opdam, '76; Nikundiwe and Nieuwenhuys, '83; Nikundiwe et al., '82; Oka et al., '87a,b; Satou et al., '85; Stuesse et al., '83, '84; Székely, '76; Székely and Czeh, '76; Takei et al., '87) have reported on the structure of the motor nuclei in the brainstem of anurans, but there is no information concerning gymnoptenes. In all studies of anurans the trigeminal, facial, and glossopharyngeal nuclei are reported to be clearly separated, and usually the vagus nucleus is also distinctly separated from the glossopharyngeal. Only in *Xenopus* (Nikundiwe and Nieuwenhuys, '83) has no separation between the glossopharyngeal and vagus nuclei been found, but that at study was based on Nissl and Kluever-Barrera methods. Thus the organization and topographical relationships of the facial nucleus, in particular, differ strongly between salamanders and anurans. The *genu facialis* is not present in anurans (Oka et al., '87b; personal observations). The glossopharyngeal and vagus nuclei play major roles in tongue projection in salamanders but are not involved with tongue projection in anurans. Oka et al. ('87a) have reported a column of preganglionic parasympathetic neurons of the facial, glossopharyngeal, and vagus nerves occupying a more dorsal position than the branchial motor column in *Bufo japonicus*. These authors believe that the more dorsal column of the facial and glossopharyngeal nerves might be homologous to the salivatory nucleus and that of the vagus to the dorsal motor nucleus of amniotes. A similar distinction between dorsal and ventral motor columns does not seem to exist in salamanders.

In contrast to the commonly held notion that striking differences in behavior are accompanied by differences in neuroanatomy, such was not the case in this study. However, we do find some important differences in neuroanatomy that correlate with differences in ontogeny and function in the bolitoglossine salamanders. These differences, at the level of cytoarchitecture of the motor nuclei, are seen more clearly in the cervical spinal cord (Wake et al., '88) than in the brainstem. The brainstem seems to be a very stable area from a phylogenetic perspective, whereas the obex region and the cervical spinal cord are more subject to variation. Results of the present study suggest that differences in peripheral structures, rather than in central nervous system structures, are the most obvious and readily observed aspect of specialization for feeding in salamanders, as suggested earlier (Lombard and Wake, '77; Thexton et al., '77; Wake, '82).

ACKNOWLEDGMENTS

We conducted some of the research reported herein at the Highlands Biological Station, NC (Richard C. Bruce, executive director), and at the Center for Cell and Molecular Biology of the University of Costa Rica (Pedro Leon and Rodrigo Gamez, directors), and we are grateful for facilities and support provided to us. Technical assistance has been provided by Monika Ernst. This research was supported by grants from DFG (to Roth) and NSF (INT-8521367 and BSR-8619630 to Wake). Nishikawa was supported by a research fellowship of the Miller Institute for Basic Research in Science, Berkeley.

LITERATURE CITED

- Alberch, P., and J. Alberch (1981) Heterochronic mechanisms of morphological diversification and evolutionary change in the neotropical salamander, *Bolitoglossa occidentalis*. *J. Morphol.* 167:249-264.
- Harrison, J.R. (1967) Observations on the life history, ecology and distribution of *Desmognathus aeneus* Brown and Bishop. *Am. Midl. Nat.* 77:356-370.
- Herrick, C.J. (1930) The medulla oblongata of *Necturus*. *J. Comp. Neurol.* 50:1-96.
- Leghissa, S. (1949) Ricerche anatomo-comparative sul sistema longitudinale mediale nella serie dei vertebrati. *Comment. Pont. Acad. Sci.* 13:153-196.
- Lombard, R.E., and D.B. Wake (1976) Tongue evolution in lungless salamanders, family Plethodontidae. I. Introduction, theory and a general model of dynamics. *J. Morphol.* 148:265-286.
- Lombard, R.E., and D.B. Wake (1977) Tongue evolution in lungless salamanders, family Plethodontidae. II. Function and evolutionary diversity. *J. Morphol.* 153:39-80.
- Lombard R.E., and D.B. Wake (1986) Tongue evolution in lungless salamanders, family Plethodontidae. IV. Phylogeny of plethodontid salamanders and the evolution of feeding dynamics. *Syst. Zool.* 35:532-551.
- Matesz, C., and G. Székely (1977) The dorsomedial nuclear group of cranial nerves in the frog. *Acta Biol. Acad. Sci. Hung.* 28(4):461-474.
- Matesz, C., and G. Székely (1978) The motor column and sensory projections of the branchial cranial nerves in the frog. *J. Comp. Neurol.* 164:47-62.
- Matsushima, T., M. Satou, and K. Ueda (1986) Glossopharyngeal and tectal influences on tongue-muscle motoneurons in the Japanese toad. *Brain Res.* 365:198-203.
- Naujoks-Manteuffel, C., G. Manteuffel, and W. Himstedt (1986) Localization of motoneurons innervating the extraocular muscles in *Salamandra salamandra* L. (Amphibia, Urodela). *J. Comp. Neurol.* 254:133-141.
- Nieuwenhuys, R., and P. Opdam (1976) Structure of the brainstem. In R. Llinas and W. Precht (eds): *Frog Neurobiology*. Berlin: Springer, pp. 811-855.
- Nikundiwe, A.M., and R. Nieuwenhuys (1983) The cell masses in the brainstem of the South African clawed frog *Xenopus laevis*: A topographic and topological analysis. *J. Comp. Neurol.* 213:199-219.
- Nikundiwe, A.M., R. de Boer-van Huizen, and H.J. ten Donkelaar (1982) Dorsal root projections in the clawed toad (*Xenopus laevis*) as demonstrated by anterograde labeling with horseradish peroxidase. *Neurosciences* 7:2089-2103.
- Oka, Y., H. Takeuchi, M. Satou, and K. Ueda (1987a) Morphology and distribution of the preganglionic parasympathetic neurons of the facial, glossopharyngeal and vagus nerves in the Japanese toad: A cobaltic lysine study. *Brain Res.* 400:389-395.
- Oka, Y., H. Takeuchi, M. Satou, and K. Ueda (1987b) Cobaltic lysine study of the morphology and distribution of the cranial nerve efferent neurons (motoneurons and preganglionic parasympathetic neurons) and rostral spinal motoneurons in the Japanese toad. *J. Comp. Neurol.* 259:400-423.
- Opdam, P., and R. Nieuwenhuys (1976) Topological analysis of the brain stem of the axolotl *Ambystoma mexicanum*. *J. Comp. Neurol.* 165:285-306.
- Roth, G. (1987) *Visual Behavior in Salamanders*. New York: Springer.
- Roth, G., and D.B. Wake (1985a) The structure of the brainstem and cervical spinal cord in lungless salamanders (family Plethodontidae) and its relation to feeding. *J. Comp. Neurol.* 241:99-110.
- Roth, G., and D.B. Wake (1985b) Trends in the functional morphology and

- sensorimotor control of feeding behavior in salamanders: An example of the role of internal dynamics in evolution. *Acta Biotheor.* (Leiden) 34:175-192.
- Roth, G., D.B. Wake, M.H. Wake, and G. Rettig (1984) Distribution of accessory and hypoglossal nerves in the hindbrain and spinal cord of lungless salamanders, family Plethodontidae. *Neurosci. Lett.* 44:53-57.
- Satou, M., T. Matsushima, H. Takeuchi, and K. Ueda (1985) Tongue-muscle-controlling motoneurons in the Japanese toad, *Bufo japonicus*: Topography, morphology and neuronal pathways for their activation and inhibition by descending volleys from the optic tectum. *J. Comp. Physiol [A]* 157:717-737.
- Stuesse, S.L., W.L.R. Cruce, and K.S. Powell (1983) Afferent and efferent components of the hypoglossal nerve in the grass frog *Rana pipiens*. *J. Comp. Neurol.* 217:432-439.
- Stuesse, S.L., W.L.R. Cruce, and K.S. Powell (1984) Organization within the cranial IX-X complex in ranid frogs: A horseradish peroxidase transport study. *J. Comp. Neurol.* 222:358-365.
- Székely, G. (1976) The morphology of motoneurons and dorsal root fibers in the frog's spinal cord. *Brain Res.* 103:275-290.
- Székely, G., and G. Czeh (1976) Organization of locomotion. In R. Llinas and W. Precht (eds): *Frog Neurobiology*. Berlin: Springer, pp. 765-792.
- Takei, K., Y. Oka, M. Satou, and K. Ueda (1987) Distribution of motoneurons involved in the prey-catching behavior in the Japanese toad, *Bufo japonicus*. *Brain Res.* 410:395-400.
- Thexton, A.J., D.B. Wake, and M.H. Wake (1977) Control of tongue function in the salamander *Bolitoglossa occidentalis*. *Arch. Oral Biol.* 22:361-366.
- Wake, D.B. (1966) Comparative osteology and evolution of the lungless salamanders, family Plethodontidae. *Mem. South. Calif. Acad. Sci.* 4:1-111.
- Wake, D.B. (1980) Evidence of heterochronic evolution: A nasal bone in the Olympic salamander, *Rhyacotriton olympicus*. *J. Herpetol.* 14:292-295.
- Wake, D.B. (1982) Functional and developmental constraints and opportunities in the evolution of feeding systems in urodeles. In D. Mossakowski and G. Roth (eds): *Environmental Adaptation and Evolution*. Stuttgart: G. Fischer, pp. 51-66.
- Wake, D.B., G. Roth, and M.H. Wake (1983) Tongue evolution in lungless salamanders, family Plethodontidae. III. Patterns of peripheral innervation. *J. Morphol.* 178:207-224.
- Wake, D.B., G. Roth, and K.C. Nishikawa (1987) The fate of the lateral line system in plethodontid salamanders. *Am. Zool.* 27:166A.
- Wake, D.B., K. Nishikawa, U. Dicke, and G. Roth (1988) Organization of the motor nuclei in the cervical spinal cord of salamanders. *J. Comp. Neurol.* 278:195-208.